

Double-low protocol for hepatic dynamic CT scan

Effect of low tube voltage and low-dose iodine contrast agent on image quality

Xiuli Zhang (MD)^a, Shaodong Li (MD)^a, Wenlou Liu (MD)^c, Ning Huang (MD)^d, Jingjing Li (MD, PhD)^{a,b}, Li Cheng (MD)^a, Kai Xu (MD, PhD)^{a,b,*}

Abstract

The radiation-induced carcinogenesis from computed tomography (CT) and iodine contrast agent induced nephropathy has attracted international attention. The reduction of the radiation dose and iodine intake in CT scan is always a direction for researchers to strive. The purpose of this study was to evaluate the feasibility of a “double-low” (i.e., low tube voltage and low-dose iodine contrast agent) scanning protocol for dynamic hepatic CT with the adaptive statistical iterative reconstruction (ASIR) in patients with a body mass index (BMI) of 18.5 to 27.9 kg/m².

A total of 128 consecutive patients with a BMI between 18.5 and 27.9 kg/m² were randomly assigned into 3 groups according to tube voltage, iodine contrast agent, and reconstruction algorithms. Group A (the “double-low” protocol): 100 kVp tube voltage with 40% ASIR, iodixanol at 270 mg I/mL, group B: 120 kVp tube voltage with filtered back projection (FBP), iodixanol at 270 mg I/mL, and group C: 120 kVp tube voltage with FBP, ioversol at 350 mg I/mL.

The volume CT dose index (CTDI_{vol}) and effective dose (ED) in group A were lower than those in group B and C (all $P < 0.01$). The iodine intake in group A was decreased by approximately 26.5% than group C, whereas no statistical difference was observed between group A and B ($P > 0.05$). There was no significant difference of the CT values between group A and C ($P > 0.05$), which both showed higher CT values than that in group B ($P < 0.001$). However, no statistical difference was observed in the contrast-to-noise ratio (CNR), the signal-to-noise ratio (SNR), and image-quality scores among the 3 groups (all $P > 0.05$). Near-perfect consistency of the evaluation for group A, B, and C (Kenall's $W = 0.921, 0.874, \text{ and } 0.949$, respectively) was obtained by the 4 readers with respect to the overall image quality.

These results suggested that the “double-low” protocol with ASIR algorithm for multi-phase hepatic CT scan can dramatically decrease radiation dose and iodine intake with adequate image quality in patients with BMI of 18.5 to 27.9 kg/m².

Abbreviations: ASIR = adaptive statistical iterative reconstruction, BMI = body mass index, CNR = contrast-to-noise ratio, CTDI_{vol} = volume CT dose index, DLP = dose-length products, ED = effective dose, FBP = filtered back projection, HAP = hepatic arterial phase, PVP = portal venous phase, LHL = left hepatic lobe, RAHL = right anterior hepatic lobe, RPHL = right posterior hepatic lobe, ROI = region of interest, SNR = signal-to-noise ratio.

Keywords: contrast agent, hepatic dynamic CT, iterative reconstruction, low-dose CT

Editor: Yong Eun Chung.

Authorship: XLZ and SDL contributed equally to this study. KX and XLZ conceived and designed the experiments. XLZ performed the experiments. XLZ and SDL analyzed the data. XLZ, WLL, NH, JLL, and LC contributed reagents/materials/methods. XLZ and SDL wrote the manuscript. All authors read and approved the final manuscript.

Funding: This study was supported by the National Natural Science Foundation of China (No. 81470075).

The authors have no conflicts of interest to disclose.

^a Department of Radiology, Affiliated Hospital of Xuzhou Medical University, ^b School of Medical Imaging, Xuzhou Medical University, Xuzhou, ^c Department of Oncology, Zhongnan Hospital of Wuhan University, Wuhan, ^d GE Life Science, Beijing, P. R. China.

* Correspondence: Kai Xu, Department of Radiology, Affiliated Hospital of Xuzhou Medical University, School of Medical Imaging, Xuzhou Medical University, No. 99 West Huai-hai Road, Xuzhou 221004, China (e-mail: xkpaper@163.com).

Copyright © 2016 the Author(s). Published by Wolters Kluwer Health, Inc. All rights reserved.

This is an open access article distributed under the Creative Commons Attribution-NoDerivatives License 4.0, which allows for redistribution, commercial and non-commercial, as long as it is passed along unchanged and in whole, with credit to the author.

Medicine (2016) 95:26(e4004)

Received: 3 December 2015 / Received in final form: 25 April 2016 / Accepted: 1 June 2016

<http://dx.doi.org/10.1097/MD.0000000000004004>

1. Introduction

Multidetector-row computed tomography (MDCT) as a useful diagnostic method has been widely applied to detect hepatic tumors and other nontumor diseases,^[1] with numerous protocols reported on dynamic contrast agent enhanced MDCT imaging of the adult abdomen.^[2] For abdominal CT, the use of insufficient contrast agent would result in ineffective contrast enhancement, hampering the accurate diagnosis of lesions in solid organs, particularly the liver, spleen, and pancreas. Otherwise, excessive contrast agent would lead to unnecessary increase in cost and the risky for organ parenchymal toxicity.^[3,4] Thus, a suitable contrast agent dose is necessary for patients' health and doctors' diagnosis.

Radiation dose during the hepatic dynamic CT scan is also a concern because it typically contains 2 or 3 phases, particularly in patients with chronic diseases or malignant tumor who have to undergo repeated diagnostic and follow-up CT examinations. Thus, the equilibrium between optimal image quality and minimized radiation dose has garnered concern worldwide.

Currently, strategies to minimize radiation dose and iodine intake at MDCT mainly involve reducing tube voltage, tube output and tube current modulation, and the introduction of noise-reducing reconstruction techniques.^[5-7] Scanning with

“double-low” protocol benefits the reduced radiation dose and iodine intake, and has been widely used in CT angiography.^[8–10] To verify whether “double-low” protocol is applicable to solid organs, a clinical trial by reducing tube voltage from 120 to 80 kVp revealed the decrease in radiation dose by 65% in hepatic arterial phase (HAP, 3.41 vs 2.97 mSv, $P < 0.01$).^[11] But unfortunately, unexpected poor image quality was obtained, presumably due to the increased image noise, decreased X-ray photons, and strengthened beam-hardening artifacts.^[12,13]

An iterative algorithm for CT is reportedly useful for reducing the quantum noise associated with reconstruction of filtered back projection (FBP), which has the drawback of oversmoothing images,^[14] while adaptive statistical iterative reconstruction (ASIR) preferably enhances image spatial resolution with little impact on image texture alterations.^[15,16] Low tube voltage (80 kVp) coupled with ASIR for hepatic dynamic CT in lean adults (mean body weight: 54.1 kg) dramatically decreased radiation dose and iodine intake, with efficient image quality.^[12] In a similar work, “double-low” hepatic CT scan was also used for patients with lighter body weight.^[11,12,17] To our knowledge, there is a paucity of literature available regarding protocols with reduced low tube voltage and reduced iodine dose contrast agent in combination with ASIR for hepatic CT scan on normal weight and overweight patients. Accordingly, our inclusion criteria for patients undergoing 100 kVp hepatic CT scan are based on BMI rather than body weight.

This study was designed to evaluate the feasibility of “double-low” protocol involving a low tube voltage (100 kVp) combined with ASIR and low-dose iodine contrast agents (270 mg I/mL) in hepatic dynamic CT scan for patients with a BMI of 18.5 to 27.9 kg/m². The advent of iodixanol (270 mg I/mL), a third-generation contrast agent, is characterized by low iodine concentration and osmotic pressure isotonic with plasma. Despite their wide application in low-dose CT studies,^[18,19] the second-generation low-osmolar contrast agents remain highly risky for organ parenchymal toxicity, especially in patients with mild renal insufficiency. Thus, in our study, iodixanol (270 mg I/mL) was designated in the “double-low” hepatic CT scan, with image quality, iodine intake, and radiation dose as evaluation indexes.

2. Methods

2.1. Patient characteristics

Our present prospective study was approved by institutional review board of the Affiliated Hospital of Xuzhou Medical University, Xuzhou, China, and patients or their legally

authorized representatives provided written informed consent before participation. Between October 2014 and January 2015, 132 patients (75 men and 57 women) were enrolled. BMI was calculated as weight in kilograms divided by the square of height in meters (kg/m²). The guidelines set by the World Health Organization^[20] are not suited to the Chinese population due to ethnic differences; according to the Guidelines for Prevention and Control of Overweight and Obesity in Chinese Adults,^[21] the patients with normal weight ($18.5 \leq \text{BMI} < 23.9 \text{ kg/m}^2$) and overweight ($24.0 \leq \text{BMI} < 27.9 \text{ kg/m}^2$) were selected. As most trials adopted an X-ray dose of 80 kVp for lean patients,^[11,12,22] which would be inadequate for patients with larger size, and hence 100 kVp was designated in our study for all patients with BMI ranging between 18.5 and 27.9 kg/m².

Inclusion criteria included hepatitis; suspected hepatocellular carcinoma (HCC); focal hepatic lesion or suspected space-occupying lesions by ultrasonography; elevated levels of tumor marker (α -fetoprotein); BMI between 18.5 and 27.9 kg/m². Exclusion criteria included gestation or lactation; moderate to severe renal failure, defined as $\text{eGFR} < 60 \text{ mL/min/1.73 m}^2$; hyperthyroidism; iodine allergy. On the basis of these criteria, 4 out of 132 patients (3.03%), that is, 2 with $\text{eGFR} < 60 \text{ mL/min/1.73 m}^2$ and 2 with $\text{BMI} \geq 28 \text{ kg/m}^2$ were excluded. A flowchart of our study is shown in Fig. 1. Thus, the remaining 128 patients were randomized into 3 groups: group A ($n=40$), group B ($n=47$), and group C ($n=41$), with the mean age = 53.3 ± 12 years (range, 24–81 years); mean height = $1.65 \pm 0.07 \text{ m}$ (range, 1.50–1.79 m); mean weight = $65.3 \pm 8.5 \text{ kg}$ (range, 47–85 kg); mean BMI = 23.76 ± 2.33 (range, 18.7–27.9 kg/m²).

2.2. CT scanning and contrast agent infusion protocols

All patients scheduled for hepatic CT scan with 128-row CT machine (GE Optima CT660; GE Healthcare, Waukesha, WI) were randomized into 3 groups: group A, (i.e., “double-low”) for dynamic CT scan at 100 kVp and an iodine concentration of iodixanol 270 mg I/mL (GE Healthcare Cork, Ireland) and a setting of 40%, ASIR; iodixanol 270 mg I/mL administered in group B and ioversol 350 mg I/mL (Tyco Healthcare, Montreal, Quebec, Canada) in group C, except for the shared 120 kVp and FBP. The dose of contrast agent was based on the patient’s body weight with a standard of 1.0 mL/kg across groups.

Except for the differences in tube voltages and image reconstruction modalities as aforementioned, other scan parameters were constant across groups, including rotation time, 0.6 or 0.5 second; beam collimation, $64 \times 0.625 \text{ mm}$; section thickness and interval,

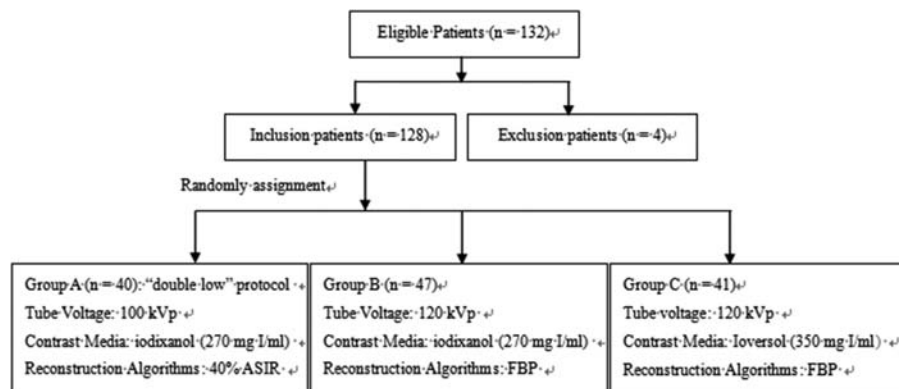


Figure 1. Flowchart of this study population enrollment. ASIR=adaptive statistical iterative reconstruction, FBP=filtered back projection.

5.0 mm; helical pitch (beam pitch), 0.984; scanning FOV, 35 cm² as well as the auto mAs (noise index = 13.0). Scans commenced with the top of the liver and proceeded cephalocaudally, with unenhanced, HAP, and portal venous phase (PVP) obtained.

An automatic scan-triggering program (SmartPrep; GE Healthcare) was employed to initiate the scanning for HAP after contrast agent injection. The region-of-interest (ROI) cursor (0.8–2.0 cm²) was placed in the abdominal aorta (AA) at the L1 level and the attenuation was assessed by 2 experienced radiology technicians. The trigger threshold was set at 150 Hounsfield units (HU), followed by PVP after a delay of 38 seconds. A 20-gauge catheter was inserted into an antecubital vein. The contrast agent was delivered at 4 mL/s with a contrast enhancement injector (Dual Shot; Nemoto Kyorindo, Tokyo, Japan), followed by 30 mL normal saline likewise injected for flush.

2.3. Measurements of radiation dose and iodine intake in CT scanning

The CTDI_{vol} and dose-length products (DLPs) were recorded in HAP and PVP for each patient. The effective doses (EDs) of both arterial and venous phases were calculated with the following equation: ED = DLP × K, where K was tissue-weighting factors of 0.016 mSv mGy cm⁻¹ for liver.^[2,3] The equation of iodine intake for each patient: Iodine intake (mg I) of group A and B = weight (kg) × 1 mL/kg × 270 mg I/mL. Iodine intake (mg I) of group C = weight (kg) × 1 mL/kg × 350 mg I/mL.

2.4. Quantitative image analysis

Quantitative analysis was performed using a commercially available workstation (Advantage Workstation 4.5; GE Healthcare, Milwaukee, WI) by 2 board-certified radiologists with 11 years of experiment in hepatobiliary imaging blinded to the diagnostic results and CT parameters. The 5-mm thick transverse images for each patient were displayed in a preset soft tissue window (window width, 300 HU; window level, 50 HU), which permitted measurements of mean attenuation of the AA on HAP and the portal vein (PV) as well as hepatic parenchyma on PVP with a circular ROI. To minimize the possible bias from single measurements, the average of the measurements from 3 continuous sections for each ROI was calculated.

The CT attenuations were assessed in both AA at the level of dome in HAP and the main PV at the hepatic hilar level in PVP. ROIs of approximately 100 mm² in the AA and PV were selected, as the sizes were adequate for pixel efficiency and exemption from interference from the vessel wall or perivascular fat. Calcified and/or soft plaques on the aortic wall were obviated with caution.

The attenuation of the hepatic parenchyma was measured in 3 ROIs in the left hepatic lobe (LHL), right anterior hepatic lobe (RAHL), and right posterior hepatic lobe (RPHL) on

images obtained at the level of the main PV, and all attenuation values were averaged. ROI area was approximately 150 mm² (range, 80–200 mm²). Areas of focal parenchymal lesions of liver, visible blood vessels, bile ducts, and artifacts were carefully avoided.

To estimate the image noise, the standard deviation (SD) of attenuation in HU was determined from each 100 mm² ROI in psoas major (ROI muscle) and lateral subcutaneous adipose tissues with 3 consecutive axial sections at the L2 level,^[2,4] with the mean SD value (SD_n) calculated as the image noise. The SNR and CNR were calculated by the following equations: SNR = ROI₀/SD_n, CNR = (ROI₀ - ROI₁)/SD_n (ROI₀ = mean ROI attenuation, ROI₁ = mean psoas major attenuation).^[1,7]

2.5. Qualitative image analysis

Four board-certified radiologists specialized in abdominal CT, who were unaware of the clinical data and the CT parameters, assessed the images independently. Adjustment of the window level and width was identical to the quantitative assessment. Overall image quality was assessed on a 4-point subjective scale (1, unacceptable; 2, acceptable; 3, good; 4, excellent), based on the noise, streak artifacts, and image sharpness.^[1,2] The score of 4 represents null for noise and streak artifacts on the image, and the sharpest image boundary; 3 stands for mild image noise and streak artifacts, with the above-average image boundary; 2 indicates moderate image noise and streak artifacts without affecting diagnosis, below-average image boundary; 1 interprets severe image noise and streak artifacts that may severely hamper diagnosis, and the blurry image boundary.

2.6. Statistical analysis

All quantitative data were shown as the mean ± SD. A 1-way analysis of variance (ANOVA) was used to assess for statistically significant differences in patient height, weight, BMI, CT value, SNR, CNR, CTDI_{vol}, ED, and iodine intake. The subjective scores of image quality were compared using the Kruskal–Wallis test. The consistency of the evaluation for image quality by the 4 radiologists was performed with the Kendall coefficient of concordance (W). The Kendall W ranged from 0 to 1, and the closer to 1 indicated the higher agreement among experts, better coordination degree, as well as more reliable results. All statistical analyses were performed with SPSS version 17.0 (SPSS Institute, Chicago, IL). Two-sided P < 0.05 was considered as statistically significant.

3. Results

3.1. Patient demographics

The patient information of each protocol is listed in Table 1. There was no significant intergroup difference with regards to age

Table 1
Patient information for the 3 groups.

Group	N	Gender (M/F)	Age, y		Height, m		Weight, kg		BMI, kg/m ²	
			Mean ± SD	Range	Mean ± SD	Range	Mean ± SD	Range	Mean ± SD	Range
A	40	23/17	55.02 ± 11.83	29–78	1.64 ± 0.75	1.50–1.79	64.11 ± 7.78	47–82	23.84 ± 2.14	19.03–27.12
B	47	27/20	51.40 ± 13.62	24–75	1.66 ± 0.66	1.50–1.79	64.55 ± 9.12	47–80	23.50 ± 2.61	19.07–27.68
C	41	24/17	55.24 ± 10.45	27–81	1.67 ± 0.69	1.55–1.78	67.32 ± 8.55	49–85	23.99 ± 2.19	18.73–27.78
F _{0.1} ²		0.817	1.413		2.455		1.712		0.512	
P		0.665	0.247		0.090		0.185		0.601	

BMI = body mass index.

Table 2**Radiation dose and iodine intake of the 3 groups.**

Group	CTDI _{vol} (mGy)		ED (mSv)		Mean iodine intake, mg I
	HAP	PVP	HAP	PVP	
A	9.88 ± 2.52*	9.86 ± 2.50*	4.28 ± 1.31*	4.27 ± 1.30*	17,310.38 ± 2099.32
B	13.59 ± 1.62	13.60 ± 1.60	5.37 ± 1.10	5.35 ± 1.10	17,429.36 ± 2464.55
C	13.81 ± 1.45	13.81 ± 1.44	5.42 ± 0.69	5.40 ± 0.67	23,560.21 ± 3843.04†
F	55.557	56.431	15.024	14.904	82.431
P	<0.001	<0.001	<0.001	<0.001	<0.001

Data are shown as mean ± SD.

CTDI_{vol} = volume CT dose index, ED = effective dose, HAP = hepatic arterial phase, PVP = portal venous phase.

* $P < 0.001$ versus Group B, or Group C.

† $P < 0.001$ versus Group A, or Group B.

($P = 0.247$), gender ($P = 0.665$), height ($P = 0.09$), body weight ($P = 0.185$), and BMI ($P = 0.601$).

3.2. Radiation dose and iodine intake

Radiation dose evaluated by the determination of CTDI_{vol} and ED and iodine intake values were studied for each protocol. As summarized in Table 2, although no significant difference was observed between group B and C ($P > 0.05$), the CTDI_{vol} for the HAP and PVP in group A (“double-low” protocol) were significantly lower than those in group B (9.88 mGy ± 2.52 vs 13.59 mGy ± 1.62, 9.86 mGy ± 2.50 vs 13.60 mGy ± 1.60, respectively, $P < 0.001$). The same trend was observed between group A and C (9.88 mGy ± 2.52 vs 13.81 mGy ± 1.45, 9.86 mGy ± 2.50 vs 13.81 mGy ± 1.44).

Compared with group B, the ED in group A was 20.3% lower for the HAP and 20.2% lower for the PVP (4.28 mSv ± 1.31 vs 5.37 mSv ± 1.10, 4.27 mSv ± 1.30 vs 5.35 mSv ± 1.10, respectively, $P < 0.001$). Similarly, the ED in group A was 21.0% lower for the HAP and 20.9% lower for the PVP than that in group C (4.28 ± 1.31 mSv vs 5.42 mSv ± 0.69, 4.27 mSv ± 1.30 vs 5.40 mSv ± 0.67, $P < 0.001$). No significant difference was observed between group B and C ($P > 0.05$).

The mean iodine intake of the patients in group A was decreased by 26.5% versus group C (17,310.38 mg I ± 2099.32 vs 23,560.21 mg I ± 3843.04, $P < 0.001$), whereas no statistical difference was observed between group A and B ($P > 0.05$).

3.3. Quantitative image analysis

The mean CT values for the AA, PV, and hepatic parenchyma (LHL, RAHL, and RPHL) of the patients in groups A (“double-low” protocol) and C showed no significant difference ($P > 0.05$), which both showed higher CT values than that in group B (all $P < 0.001$) (Table 3). Compared with group B, the mean CT values in

group A were increased by 24.1% for AA, 13.3% for PV, 8.4% for LHL, 6.8% for RAHL, and 6.5% for RPHL (all $P < 0.001$).

The SNR and CNR of AA, PV, LHL, RAHL, and RPHL in 3 groups are summarized in Tables 4 and 5. In all hepatic phases, the SNR and CNR of each ROI in 3 groups were calculated, and no statistically significant difference was observed (all $P > 0.05$), suggesting that the “double-low” protocol was able to result in satisfied SNR and CNR that were identical to group B and C.

3.4. Qualitative image analysis

Mean qualitative grades of the images in the 3 groups are summarized in Table 6. One case in “double-low” protocol was assessed as unacceptable by reader 1 and 2 because of the mobile artifact. No case was graded as unacceptable (score of 1) in group B and C, meaning that none was considered as nondiagnostic or inadequate image quality. However, overall image quality scores in the 3 groups, including the noise, streak artifacts, and image sharpness, had no statistically significant difference evaluated by the 4 readers (reader 1: $P = 0.409$, reader 2: $P = 0.731$, read 3: $P = 0.338$, read 4: $P = 0.910$). Near-perfect consistency of the evaluation for group A, B, and C (Kenall $W = 0.921$, 0.874, and 0.949, respectively) was obtained by the 4 readers. Representative case for each group is shown in Fig. 2.

4. Discussion

Our findings revealed that “double-low” protocol for hepatic dynamic CT could dramatically reduce radiation dose and iodine intake in patients with a BMI of 18.5 to 27.9 kg/m², with adequate image diagnostic utility.

The “double-low” protocol could generate almost identical SNR, CNR, and image-quality scores compared with group B, with the increased CT values (AA: 24.1%; PV: 13.3%; HLL: 8.4%; RAHL: 6.8%; RPHL: 6.5%) and the reduced ED (HAP:

Table 3**CT values (HU) of vessels and hepatic parenchyma in the 3 groups.**

Group	AA	PV	LHL	RAHL	RPHL
A	263.56 ± 46.69	119.11 ± 11.99	95.38 ± 8.37	94.74 ± 8.92	93.03 ± 10.22
B	212.41 ± 41.44*	105.11 ± 14.39*	88.01 ± 9.96*	88.68 ± 9.03*	87.37 ± 10.25*
C	259.76 ± 30.57	115.36 ± 12.31	92.71 ± 7.68	93.33 ± 5.98	92.30 ± 7.84
F	22.464	13.677	7.912	6.701	4.632
P	<0.001	<0.001	0.001	0.002	0.011

Data are shown as mean ± SD.

AA = abdominal aorta, PV = portal vein, HLL = hepatic left lobe, RAHL = right anterior hepatic lobe, RPHL = right posterior hepatic lobe.

* $P < 0.001$ versus Group A, or Group C.

Table 4

The signal-to-noise ratio of vessels and hepatic parenchyma in the 3 groups.

Group	AA	PV	LHL	RAHL	RPHL
A	23.27 ± 8.93	11.95 ± 4.95	11.12 ± 1.96	11.68 ± 5.65	10.44 ± 3.09
B	23.73 ± 9.75	14.08 ± 8.99	13.46 ± 5.68	12.52 ± 4.39	13.43 ± 9.64
C	25.71 ± 6.87	13.05 ± 3.95	12.47 ± 5.42	14.06 ± 6.89	13.08 ± 6.22
F	0.926	1.153	2.637	1.838	2.249
P	0.399	0.319	0.076	0.163	0.110

Data are shown as mean ± SD. The SNR across 3 groups had no statistical difference ($P > 0.05$). AA=abdominal aorta, PV=portal vein, LHL=hepatic left lobe, RAHL=right anterior hepatic lobe, RPHL=right posterior hepatic lobe.

Table 5

The contrast-to-noise ratio of vessels and hepatic parenchyma in the 3 groups.

Group	AA	PV	LHL	RAHL	RPHL
A	34.37 ± 12.71	9.30 ± 4.13	5.26 ± 2.22	5.22 ± 2.68	4.86 ± 2.55
B	30.24 ± 12.60	9.11 ± 5.24	5.83 ± 3.76	5.83 ± 3.31	5.59 ± 3.52
C	36.08 ± 12.63	10.16 ± 4.06	6.01 ± 2.48	6.07 ± 2.48	5.84 ± 2.66
F	2.501	0.640	0.721	0.972	1.188
P	0.086	0.529	0.488	0.381	0.308

Data are shown as mean ± SD. The CNR across 3 groups had no statistical difference ($P > 0.05$). AA=abdominal aorta, PV=portal vein, LHL=hepatic left lobe, RAHL=right anterior hepatic lobe, RPHL=right posterior hepatic lobe.

20.3%, HVP: 20.2%). So, our results suggested that at the isoconcentration of iodine solution, 100 kVp could generate a higher CT value than 120kVp. In addition, the “double-low” protocol could offer almost equivalent CT values of vessels as well as hepatic parenchyma and image quality with that acquired by higher iodine concentration (120kVp/350mg I/mL protocol), which was consistent with previous studies.^[12,25] Lower-kVp CT images at 80 or 100kVp could offer greater iodine-related attenuation than similar images scanned at 120kVp,^[25] indicating that scanning at a low tube voltage facilitated to reduce radiation dose and iodine intake because the X-ray output energy at these low voltages is closer to the iodine k edge of 33 keV. Thus, at the low-tube voltage, the lower-concentration iso-osmotic contrast agent could enhance CT values.

The CT values of the AA, PV, and hepatic parenchyma were much higher for the “double-low” protocol (the 100kVp/270 mg I/mL with 40% ASIR) than other protocols, which was consistent with previous reports.^[11,26] Nevertheless, the CT values in our study (AA: 263.56HU, PV: 119.11HU, hepatic parenchyma: 95.38HU) were lower than the result of Takahashi et al^[27] (AA: 354.3HU, PV: 148.7HU, hepatic parenchyma: 119.8HU), which might account for our lower contrast agent dose (270 mg I/kg vs 480mg I/kg) with the same tube voltage and reconstruction algorithms (100kVp and 40% ASIR). Within a certain range, the CT values are positively related to the contrast agent dose, especially for parenchymal organs and vessels.

Previous study showed that the 80kVp setting and iterative reconstruction for hepatic dynamic CT reduced the radiation and

Table 6

Image quality scores of the 3 groups.*

		Group A	Group B	Group C	χ^2	P
Reader 1	Score=4	34	44	37	1.787	0.409
	Score=3	4	2	3		
	Score=2	1	1	1		
	Score=1	1	0	0		
Reader 2	Score=4	34	42	37	0.626	0.731
	Score=3	4	4	2		
	Score=2	1	1	2		
	Score=1	1	0	0		
Reader 3	Score=4	34	44	38	2.167	0.338
	Score=3	4	2	2		
	Score=2	2	1	1		
	Score=1	0	0	0		
Reader 4	Score=4	35	42	37	0.190	0.910
	Score=3	3	4	3		
	Score=2	2	1	1		
	Score=1	0	0	0		
Kendall W		0.921	0.874	0.949		
P		<0.001	<0.001	<0.001		

* 4=excellent, 3=good, 2=acceptable, 1=unacceptable.

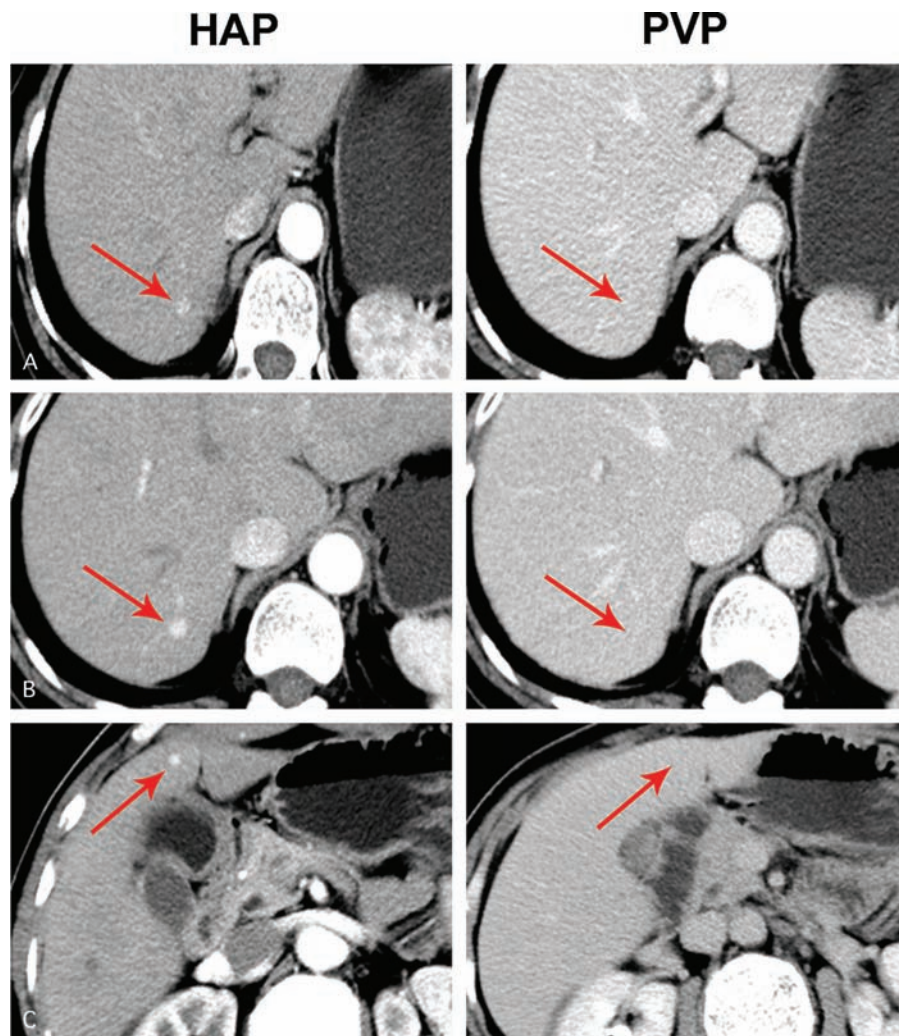


Figure 2. (A) Hepatic dynamic CT images in the HAP (CTDI_{vol}=9.52, ED=4.32) and the PVP (CTDI_{vol}=9.52, ED=4.32) of a 60-year-old woman patient (BMI=24.5 kg/m²) suffering hemangioma scanned with group A protocol. (B) Hepatic dynamic CT images in the HAP (CTDI_{vol}=13.72, ED=5.79) and the PVP (CTDI_{vol}=13.72, ED=5.79) of the same woman patient scanned with group C protocol 2 months later. (C) Hepatic dynamic CT images in the HAP (CTDI_{vol}=13.26, ED=5.23) and the PVP (CTDI_{vol}=13.26, ED=5.23) of a 56-year-old woman hemangioma patient (BMI=24.1 kg/m²) performed with group B protocol. Scoring all images was a 4 point. The arrow in the figure indicated the location of hemangioma. CTDI_{vol}=volume CT dose index, BMI=body mass index, ED=efficient dose, HAP=hepatic arterial phase, PVP=portal venous phase.

contrast agent doses in lean adults with mean body weight of 54.1 kg.^[12] In our study, 100 kVp with 40% ASIR was performed on normal and overweight patients with mean body weight of 65.3 kg (range of BMI: 18.5–27.9 kg/m²), leading to a more extensive application.

Albeit the mechanism of contrast agent induced nephropathy (CIN) remains a puzzle, nonionic iodinated contrast agent could lead to apoptosis and necrosis of renal tubular cells, and dose-related renal cell apoptosis.^[28,29] Osmotic pressure of contrast agent plays a role in the pathogenesis of CIN. Hyperosmolarity could lead to renal vasoconstriction, osmotic diuresis, and renal ischemia.^[30] Prior studies utilized second-generation low-osmotic contrast agents.^[17,18] We employed iodixanol (270 mg I/mL), a third-generation contrast agent, and a second-generation contrast agent ioversol (350 mg I/mL). Ioversol (350 mg I/mL) is hyperosmotic, which is about 2.7 times with plasma. Hyperosmosis induces increased gaps of endothelial cells and elevated vascular permeability, leading to the flow of interstitial fluid into

intravascular, diluting the contrast agent and decreasing iodine concentration of ioversol eventually.^[31,32] However, this phenomenon could not be observed in the case of iodixanol (270 mg I/mL), which is iso-osmotic to plasma (290 mOsm/kg). Therefore, we postulated that the similar CT values between 100 kVp /270 mg I/mL (“double-low” protocol) and 120 kVp /350 mg I/mL groups might be attributed to the hyperosmolarity of ioversol at least in part.

ASIR, a new reconstructive algorithm to reduce noise and ensure image quality, was introduced to our “double-low” protocol. The radiation dose is proportional to the square of the tube voltage. Thus, a reduction in tube voltage can significantly decrease the radiation dose.^[33,34] In our study, the tube voltage was reduced from 120 to 100 kVp, and the ED was decreased by 21.0% in arterial phase and 20.9% in venous phase, respectively, which was consistent with previous studies.^[11] Conventional FBP coupled with low-tube voltage would increase the noise. Previous studies had reported that comparing with conventional CT with

FBP reconstruction, the ASIR algorithm improved the image quality at a low-dose CT during the late HAP.^[34] The proportion of ASIR applied to an FBP image varies from 10% to 100%, and with the increase in ASIR proportion, the smoothening of images is progressively enhanced.^[36] The 40% ASIR was reported to be well matched with the noise context of a full-dose examination with FBP.^[37] Hence, 40% ASIR was selected in “double-low” group, presenting a similar image quality with group C (the 120 kVp with FBP) ($P > 0.05$).

Our study has several limitations. First, the accuracy of a “double-low” hepatic CT protocol in the diagnosis of liver tumors was not included in this study because we primarily focused on assessment of CT scan image quality and iodine intake. Among the 132 patients, only 46 with liver tumor were recruited in this study, which could not be exempted from biased selection. More suitable patients should be involved in the future study to evaluate the effect of the “double-low” hepatic CT protocol for the diagnostic performance on liver tumors. Second, the 40% level of ASIR image reconstruction was employed according to the literature. The efficiency of other proportions should also be tested. Last but not the least, the optimal double-low protocol of hepatic CT for patients with obesity (BMI ≥ 28 kg/m²) should be studied in the future.

In conclusion, in all hepatic phases, a low tube voltage and low-dose iodine contrast agent (i.e., double-low protocol) CT with ASIR algorithm significantly decreased radiation dose and iodine intake with efficient image quality in patients with a BMI of 18.5 to 27.9 kg/m².^[35]

References

- Onishi H, Murakami T, Kim T, et al. Hepatic metastases: detection with multidetector row CT, SPIO-enhanced MR imaging, and both techniques combined. *Radiology* 2006;239:131–8.
- Kidoh M, Nakaura T, Oda S, et al. Contrast enhancement during hepatic computed tomography: effect of total body weight, height, body mass index, blood volume, lean body weight, and body surface area. *J Comput Assist Tomogr* 2013;37:159–64.
- Onishi H, Murakami T, Kim T, et al. Abdominal multi-detector row CT: effectiveness of determining contrast medium dose on basis of body surface area. *Eur J Radiol* 2011;80:643–7.
- Kalra MK, Woisetschlager M, Dahlstrm N, et al. Radiation dose reduction with Sinogram Affirmed Iterative Reconstruction technique for abdominal computed tomography. *J Comput Assist Tomogr* 2012;36:339–46.
- Baker ME, Dong F, Primak A, et al. Contrast-to-noise ratio and low-contrast object resolution on full- and low-dose MDCT: SAFIRE versus filtered back projection in a low-contrast object phantom and in the liver. *AJR Am J Roentgenol* 2012;199:8–18.
- Schindera ST, Diedrichsen L, Muller HC, et al. Iterative reconstruction algorithm for abdominal multidetector CT at different tube voltages: assessment of diagnostic accuracy, image quality and radiation dose in a phantom study. *Radiology* 2011;260:454–62.
- Silva AC, Lawder HJ, Hara A, et al. Innovations in CT dose reduction strategy: application of the adaptive statistical iterative reconstruction algorithm. *AJR Am J Roentgenol* 2010;194:191–9.
- Sun G, Hou YB, Zhang B, et al. Application of low tube voltage coronary CT angiography with low-dose iodine contrast agent in patients with a BMI of 26–30 kg/m². *Clin Radiol* 2015;70:138–45.
- Faggioni L, Neri E, Sbragia P, et al. 80-kV pulmonary CT angiography with 40 mL of iodinated contrast material in lean patients: comparison of vascular enhancement with iodixanol (320 mg I/mL) and iomeprol (400 mg I/mL). *AJR Am J Roentgenol* 2012;199:1220–5.
- Utsunomiya D, Oda S, Funama Y, et al. Comparison of standard- and low-tube voltage MDCT angiography in patients with peripheral arterial disease. *Eur Radiol* 2010;20:2758–65.
- Yanaga Y, Awai K, Nakaura T, et al. Hepatocellular carcinoma in patients weighing 70 kg or less: initial trial of compact-bolus dynamic CT with low-dose contrast material at 80 kVp. *AJR Am J Roentgenol* 2011;196:1324–31.
- Nakaura T, Nakamura S, Maruyama N, et al. Low contrast agent and radiation dose protocol for hepatic dynamic CT of thin adults at 256-detector row CT: effect of low tube voltage and hybrid iterative reconstruction algorithm on image quality. *Radiology* 2012;264:445–54.
- Funama Y, Awai K, Nakayama Y, et al. Radiation dose reduction without degradation of low-contrast detectability at abdominal multi-section CT with a low-tube voltage technique: phantom study. *Radiology* 2005;237:905–10.
- Singh S, Kalra MK, Hsieh J, et al. Abdominal CT: comparison of adaptive statistical iterative and filtered back projection reconstruction techniques. *Radiology* 2010;257:373–83.
- Leipsic J, Labounty TM, Heilbron B, et al. Adaptive statistical iterative reconstruction: assessment of image noise and image quality in coronary CT angiography. *AJR Am J Roentgenol* 2010;195:649–54.
- Ning P, Zhu S, Shi D, et al. X-ray dose reduction in abdominal computed tomography using advanced iterative reconstruction algorithms. *PLoS One* 2014;9:e92568.
- Namimoto T, Oda S, Utsunomiya D, et al. Improvement of image quality at low-radiation dose and low-contrast material dose abdominal CT in patients with cirrhosis: intraindividual comparison of low tube voltage with iterative reconstruction algorithm and standard tube voltage. *J Comput Assist Tomogr* 2012;36:495–501.
- Kidoh M, Nakaura T, Nakamura S, et al. Low-contrast-dose protocol in cardiac CT: 20% contrast dose reduction using 100 kVp and high-tube-current-time setting in 256-slice CT. *Acta Radiol* 2014;55:545–53.
- Cho ES, Yu JS, Ahn JH, et al. Angiography of the renal arteries: comparison of lower-tube-voltage CTA with moderate-concentration iodinated contrast material and conventional CTA. *AJR Am J Roentgenol* 2012;199:96–102.
- WHO Obesity: Preventing and Managing the Global Epidemic. Report of a WHO Consultation. WHO Technical Report Series 894. Geneva: World Health Organization; 2000.
- Guo L, Li N, Wang G, et al. Body mass index and cancer incidence: a prospective cohort study in northern China. *Zhonghua Liu Xing Bing Xue Za Zhi* 2014;35:231–6.
- Guimarães LS, Fletcher JG, Harmsen WS, et al. Appropriate patient selection at abdominal dual-energy CT using 80 kV: relationship between patient size, image noise, and image quality. *Radiology* 2010;257:732–42.
- Christner JA, Kofler JM, McCollough CH. Estimating effective dose for CT using dose-length product compared with using organ doses: consequences of adopting International Commission on Radiological Protection publication 103 or dual-energy scanning. *AJR Am J Roentgenol* 2010;194:881–9.
- Kaza RK, Platt JF, Al-Hawary , et al. CT enterography at 80 kVp with adaptive statistical iterative reconstruction versus at 120 kVp with standard reconstruction: image quality, diagnostic adequacy, and dose reduction. *AJR Am J Roentgenol* 2012;198:1084–92.
- Yu L, Bruesewitz MR, Thomas KB, et al. Optimal tube potential for radiation dose reduction in pediatric CT: principles, clinical implementations, and pitfalls. *Radiographics* 2011;31:835–48.
- Nakayama Y, Awai K, Funama Y, et al. Lower tube voltage reduces contrast material and radiation doses on 16-MDCT aortography. *AJR Am J Roentgenol* 2006;187:W490–497.
- Takahashi H, Okada M, Hyodo T, et al. Can low-dose CT with iterative reconstruction reduce both the radiation dose and the amount of iodine contrast medium in a dynamic CT study of the liver? *Eur J Radiol* 2014;83:684–91.
- Zhao Y, Tao Z, Xu Z, et al. Toxic effects of a high dose of non-ionic iodinated contrast media on renal glomerular and aortic endothelial cells in aged rats in vivo. *Toxicol Lett* 2011;202:253–60.
- Huda W, Ogden KM, Khorasani MR. Converting dose-length product to effective dose at CT. *Radiology* 2008;248:995–1003.
- Sharma SK, Kini A. Effect of nonionic radiocontrast agents on the occurrence of contrast-induced nephropathy in patients with mild-moderate chronic renal insufficiency: pooled analysis of the randomized trials. *Catheter Cardiovasc Interv* 2005;65:386–93.
- Cademartiri F, Mollet NR, van der Lugt A, et al. Intravenous contrast material administration at helical 16-detector row CT coronary angiography: effect of iodine concentration on vascular attenuation. *Radiology* 2005;236:661–5.
- Tsai IC, Lee T, Tsai WL, et al. Contrast enhancement in cardiac MDCT: comparison of iodixanol 320 versus iohexol 350. *AJR Am J Roentgenol* 2008;190:W47–53.

- [33] Sabarudin A, Md Yusof AK, Tay MF, et al. Dual-source CT coronary angiography: effectiveness of radiation dose reduction with lower tube voltage. *Radiat Prot Dosimetry* 2013;153:441–7.
- [34] Sagara Y, Hara AK, Pavlicek W, et al. Abdominal CT: comparison of low-dose CT with adaptive statistical iterative reconstruction and routine-dose CT with filtered back projection in 53 patients. *AJR Am J Roentgenol* 2010;195:713–9.
- [35] Marin D, Nelson RC, Schindera ST, et al. Low-tube-voltage, high-tube-current multidetector abdominal CT: improved image quality and decreased radiation dose with adaptive statistical iterative reconstruction algorithm-initial clinical experience. *Radiology* 2010;254:145–53.
- [36] Hara AK, Paden RG, Silva AC, et al. Iterative reconstruction technique for reducing body radiation dose at CT: feasibility study. *AJR Am J Roentgenol* 2009;193:764–71.
- [37] Tanikake M, Shimizu T, Narabayashi I, et al. Three-dimensional CT angiography of the hepatic artery: use of multi-detector row helical CT and a contrast agent. *Radiology* 2003;227:883–9.